

## Adult & Paediatric Resting Electrocardiography (ECG)

### Cardiac Sciences

**Custodian/Review Officer:**

Chief Allied Health Officer

**Version no:** 1.0

**Applicable To:**

All health practitioners

**Approval Date:** 26/11/2012

**Effective Date:** 26/11/2012

**Next Review Date:** 26/11/2013

**Authority:**

Chair – State-wide clinical measurements network

**Approving Officer:**

Chief Allied Health Officer

**Supersedes:** New document

**Key Words:** ECG, EKG, electrocardiography, electrocardiograph, 12-lead, resting ECG

**Accreditation References:**

EQulP and other criteria and standards

### 1. Purpose

This guideline provides recommendations regarding best practice to support high quality resting electrocardiography (ECG) practice throughout Queensland Health facilities.

### 2. Scope

This guideline provides information for all health practitioners who perform routine resting adult and paediatric ECGs as part of their clinical duties.

This guideline does not relate to ECGs for the purpose of exercise stress testing, ambulatory ECG (Holter) monitoring, signal averaged ECG or mobile telemetry.

This guideline provides the minimum requirements for recording a routine resting 12 lead ECG in clinical practice (with variations for right sided, 15 lead, dextrocardia and paediatric populations).

### 3. Related documents

**Policy and Standard/s:**

- [Informed Decision-making in Healthcare](#) (QH-POL-346:2011) <sup>1</sup>

**Procedures, Guidelines, Protocols**

- [Australian Guidelines for the prevention and control of infection in healthcare](#) (CD33:2010) <sup>2</sup>
- American Heart Association (AHA) Electrocardiography Guidelines Part 1 & 2 (2007) <sup>3, 4</sup>
- ACC/AHA clinical competence statement on electrocardiography and ambulatory electrocardiography <sup>5</sup>
- The Society for Cardiological Science and Technology, British Cardiovascular Society, Clinical Guidelines by



Consensus: Recording a standard 12 Lead electrocardiogram, an approved Methodology. (2010)<sup>6</sup>

## 4. Guideline for performing electrocardiography (ECG)

### 4.1. Emergency Protocol

- For arrest situations local emergency protocols for Code Blue should be followed.
- Record an additional rhythm strip if a significant arrhythmia is detected or a longer recording period is required<sup>3,4,6</sup> as per manufactures instructions.
- Identify any changes on the ECG that may require urgent medical attention and if required, seek advice from a senior member of staff while the patient remains connected.
- Document any cardiac symptoms on the printed ECG and bring to the immediate attention of a senior member of staff<sup>6</sup>.

### 4.2. Infection Control Procedures

- Australian Guidelines for the prevention and control of infection in healthcare (2010) <http://www.nhmrc.gov.au/node/30290>.<sup>2</sup>
- Local Hospital and Health Service Infection Control policies, procedures and guidelines.

### 4.3. Gaining Consent

- Gain consent in accordance with Queensland Health's Informed Decision-making In Healthcare Policy<sup>1</sup>.
- Make the patient aware of the requirements of the procedure and what they will be required to do.
- Offer an option of who performs the test if gender preference is considered an issue, or requested by the patient.

### 4.4. Identifying Indications / Contraindications<sup>5</sup>

#### *Indications*

- Chest pain suggestive of ischemia
- Known or suspected arrhythmias
- Changes in rhythm (eg atrial fibrillation to sinus rhythm, new bundle branch block)
- Post cardiac arrest/resuscitation
- Post syncopal episodes to assess arrhythmia
- ST/T wave changes consistent with metabolic and electrolyte disturbances
- Preoperative assessment
- Post insertion of pacemaker (permanent or temporary)

- Routine requirements
- Assessment of medications known to cause cardiac arrhythmia

## 4.5. Facilities and equipment

### *Room Preparation*

Ensure that:

- the patient area and ECG machine are clean and tidy
- the bed is adjustable and large enough to support the patient's body and limbs<sup>6</sup>
- the ECG machine is safe and ready to use. The date and time should be correct on the machine
- there is sufficient stock for performing an ECG including ECG paper, ECG electrodes, towelling, paper, hair removal device, skin prep and cleaning wipes
- hands are washed<sup>2</sup>
- staff are aware of the location of the crash trolley and emergency buttons in case of emergency

### *Minimum Equipment*

The ECG machine requirements include pre-programming the device in accordance with American Heart Association (AHA) specifications<sup>3,6</sup>:

- Set the low-frequency filter no higher than 0.05 Hz to avoid distortion of the ST segment.
- Set the high frequency filter no lower than 100 Hz to prevent loss of high frequency information.

Equipment within the room should include:

- disposable electrode tabs
- ECG paper
- skin preparation equipment (hair removal device, cleaning wipes, abrasive tape)
- adjustable bed / couch that a patient can lie on comfortably (with all limbs resting on the bed surface) and can be adjusted to the correct height for the person performing the ECG.

## 4.6. Training requirements

Obtain training to ensure you are proficient in the following areas of skill and knowledge:

- use of the ECG machine
- recording of the 12 lead ECG<sup>3</sup>
- recognition of significant and life threatening arrhythmias
- appropriate response to significant and life threatening arrhythmias



- basic life support and cardiopulmonary resuscitation as per Hospital and Health Service requirements.

## 4.7. Test Procedure

### 4.7.1. Patient preparation

- Greet the patient and introduce yourself (name and title) ensuring your ID badge is being displayed.
- Confirm patient's identity – request the patient's full name and date of birth and check the procedure to be performed (asking them if their name is John is not confirming their identity).
- Explain the procedure in detail (what an ECG is, and that the test is quick and painless).
- Inform the patient that in order to perform the ECG, unrestricted access to the chest area will be required <sup>6</sup>.
- Obtain informed consent once the procedure has been explained to the patient.
- Every effort should be made to respect the patient and minimise embarrassment by allowing them to dress and undress in private.
- The female patient should be covered (gown, sheet or towel) during the procedure to ensure their modesty.
- The patient should be in a supine position <sup>3, 6</sup>.

**Note:** The appearance of the ECG can vary depending on the position of the body. Any changes to a supine position should be documented on the printed ECG <sup>3, 6</sup>.

- The patient should be comfortable and relaxed to achieve a clinically accurate recording with minimal artefact <sup>6</sup>.

### 4.7.2. Skin preparation

To minimise the skin-to-electrode impedance, and help produce an artefact-free accurate ECG, the following techniques should be utilised to prepare the skin. <sup>6</sup>

- Shave the hair at the electrode placements site if necessary (patient consent required)<sup>6</sup>. Dispose of any sharps in the sharps container immediately after use as per local Hospital and Health Service guidelines for waste management.
- Clean the skin – this may include washing the area with a mild soap or with an alcohol wipe <sup>6</sup>. Confirm with the patient if allergies exist.
- Exfoliate if necessary with light abrasion using a paper towel, gauze swab or abrasive tape designed specifically for this purpose <sup>6</sup>.
- Care should be taken in patients with sensitive or broken skin.



### 4.7.3. Electrode placement

- The electrode placement should adhere to the recommendations and guidelines as per the American Heart Association (AHA) to ensure consistency between recordings<sup>3, 4, 6</sup>.
- Any alterations to the positions of the electrode placements should be clearly and accurately documented on the printed ECG recording<sup>3, 4, 6</sup>. This should include how and why the alteration was performed.

#### Limb Leads

- Evidence confirms that inconsistency with limb lead placement alters the appearance of the ECG<sup>3, 4, 6</sup>.
- To ensure consistency it is recommended that the limb lead electrodes are placed slightly proximal to the wrists and ankles<sup>6</sup>.

Electrode	Position
RA (Right arm)	Right forearm, proximal to the wrist
LA (Left arm)	Left forearm, proximal to the wrist
LL (Left leg)	Left lower leg, proximal to the ankle
RL (Right leg)	Right lower leg, proximal to the ankle

- If necessary alternative sites for amputees and patients with limb tremor are as per the Mason-Likar<sup>7</sup> placement described below.
- Limb leads are connected to sites on the anterior torso (deltoid fossa at the mid clavicular line) rather than distal limb sites.
- Lower limb leads are connected as distal as possible on the limbs or if unable to do so, the lower left and right anterior torso.

#### Precordial (chest) leads

- Attention should be paid to the correct placement of the precordial leads as variation can produce diagnostically significant differences to the ECG<sup>3, 4, 6</sup>.
- Correct anatomical positions have been defined and every effort should be made to always ensure correct electrode placement (see Figure 1 below)<sup>6</sup>.
- The centre of the active surface area of the electrode should be aligned with the relevant anatomical landmark<sup>3, 4, 6</sup>.

Electrode	Position
V1	Fourth intercostal space at the right sternal edge
V2	Fourth intercostal space at the left sternal edge
V3	Midway between V2 and V4
V4	Fifth intercostal space in the mid-clavicular line
V5	Left anterior axillary line at same horizontal level as V4
V6	Left mid-axillary line at same horizontal level as V4 and V5

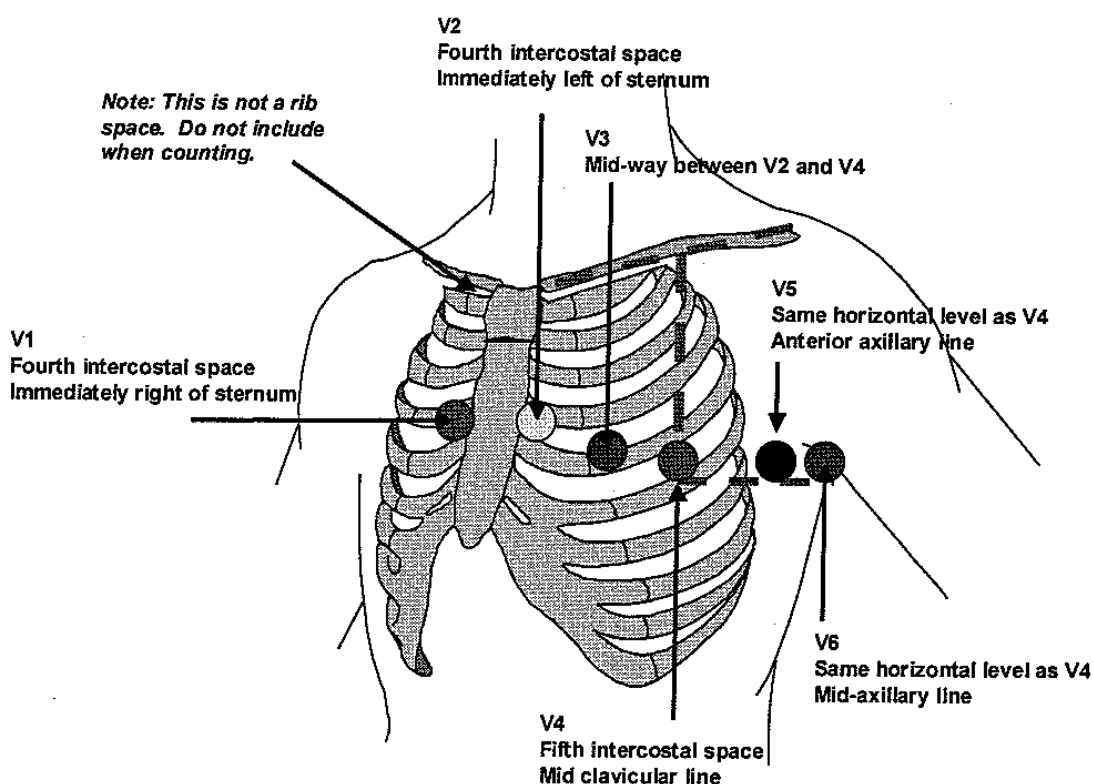


Figure 1. Standard ECG chest electrode placements <sup>6</sup>

- Please see Appendix 1 for locating the correct precordial electrode positions.

#### 4.7.4. Recording

- Enter the patient's demographic details into the machine, including name, date of birth and hospital number (unit record number (UR Number)).
- Confirm the patient's details directly with the patient before entering the details into the machine.

- Ensure the patient is relaxed and comfortable in order to reduce artefact that can cause somatic muscle potentials on the ECG<sup>3, 4, 6</sup>.
- Occasionally it may be necessary to adapt the recommended ECG recording techniques<sup>6</sup>. For example, wheelchair bound patients may need to remain in the chair. Any variations to the standard ECG recording techniques need to be documented on the printed ECG<sup>3, 4, 6</sup>.
- Ensure visual confirmation of an artefact free ECG trace on the display before pressing the appropriate record or print button on the ECG machine to obtain a resting 12 lead ECG.
- Record a 12 lead ECG at 25 mm/sec with a gain setting of 10 mm/mV<sup>3, 4, 6</sup>.
- Change the gain setting to 5 mm/mV to ensure accurate measurement if the ECG complexes are of a high voltage<sup>3, 4, 6</sup>. Ensure this change is clearly marked on the printed ECG recording.
- Do not use the bandwidth filter for the initial ECG recording<sup>6</sup>.
- If, despite efforts to relax the patient and make them comfortable, there is somatic muscle artefact on the ECG, the bandwidth filter may be switched on. Switch on the filter and repeat the recording<sup>3, 4, 6</sup>.
- Electrical equipment can interfere with the ECG recording and may need to be turned off during recording. Check that it is safe to turn off equipment, particularly medical equipment, prior to switching off.
- If a significant arrhythmia is detected or a longer recording period is required, an additional rhythm strip should be recorded<sup>3, 4, 6</sup> as per manufactures instructions.
- Ensure the printed 12 lead ECG has all the correct details. If the ECG recording is technically correct and of good quality, then the leads and electrodes may be removed from the patient<sup>6</sup>.
- Dispose of the electrodes appropriately in the waste.
- Allow the patient privacy to change into their original clothing.
- Inform the patient the test is now completed and document the ECG as per local work unit guidelines.
- Once the patient has left the room, clean the machine, leads and bed as per the Australian Guidelines for the Prevention and Control of Infection in Healthcare<sup>2</sup>.

### 4.8. Quality Control Procedures

- Refer to Section 4.5 Facilities and equipment for relevant quality control requirements for patient preparation, skin preparation, electrode placement and recording.





## 5. Definition of Terms

Definitions of key terms are provided below.

Abbreviation	Term	Definition / Explanation / Details
ECG (also EKG)	Electrocardiography	The standard 12-lead ECG records potential differences between prescribed sites on the body surface that vary during the cardiac cycle; it reflects differences in transmembrane voltages in myocardial cells that occur during depolarization and repolarization within each cycle. <sup>3</sup>
	Artefact	Interference that may impact accurate interpretation. Common examples include: 60 Hz cycle interference, muscle tremor, wandering baseline, poor electrode contact, patient movement, improper standardisation and limb lead reversal. <sup>8</sup>

## 6. Consultation

Key stakeholders (position and business area) who reviewed this version are:

- Cardiac Sciences Working Party: Dane Enkera (Senior Cardiac Scientist, Princess Alexandra Hospital), Kellie Homann (Cardiac Scientist, The Royal Brisbane & Women's Hospital), Barry Kochevatkin (Director Clinical Measurements Unit, Mackay Hospital), Elissa Ulett (A/Director Cardiac Investigations Unit, The Townsville Hospital), Daniel Wright (Cardiac Scientist, The Prince Charles Hospital), Oscar Davison (Cardiac Scientist, The Prince Charles Hospital), Justin Gordon (Paediatric Cardiac Scientist, QLD Paediatric Cardiac Services)
- Cardiac Sciences Department Directors
- Senior Cardiac Scientists
- State-wide Cardiac Clinical Network
- Northern, Central & Southern Cardiac Networks
- State-wide Clinical Measurements Network
- Clinical Measurements Advisory Group
- District Directors of Allied Health
- Allied Health Professions Office Queensland





## 7. Guideline Revision and Approval History

Version No.	Modified by	Approved by
1.0		Dane Enkera - Chair State-wide Clinical Measurements Network Brett Duce - Chair Clinical Measurements Advisory Group (for clinical education)

## 8. Appendices

### Appendix 1: Locating Chest Electrode Positions

- When counting the intercostal spaces down from the clavicle, ensure not to include the small space between the clavicle and the first rib<sup>3, 4, 6</sup>. This small space is not the first intercostal space.
- The sternal edge should be used as the main reference point to avoid this common error<sup>6</sup>. This anatomical landmark denotes the position of the sternal angle at the manubriosternal joint<sup>6</sup>.
- To locate the sternal angle – starting at the sternal notch, run the finger down the sternum until you feel a bony horizontal ridge, this is the sternal angle<sup>6</sup>.
- Once the sternal angle is located, place the finger on this ridge, slide down to the side will locate the second intercostals space. From here, count the third and fourth space<sup>6</sup>.
- V1 and V2 should be placed at the fourth intercostal space on the very edge of the sternum (V1 on the right of the sternum and V2 on the left of the sternum)<sup>3, 4, 6</sup>.
- Following the placement of V1 and V2, V4 should be located.
- V4 is placed in the fifth intercostal space in line with the mid point of the clavicle<sup>3, 4, 6</sup>.
- V3 is then placed directly mid-way between V2 and V4<sup>3, 4, 6</sup>.
- V5 and V6 are placed by following a horizontal line from V4. Ensure not to follow the line of the ribs. V5 is placed in line with the anterior axilla and V6 in line with the mid-axilla<sup>3, 4, 6</sup>.
- When recording an ECG on female patients, leads V1-V3 should be placed in the standard positions, while it is recommended that leads V4-V6 chest electrodes are placed beneath the left breast where the breast tissue meets with the chest<sup>3, 4, 6</sup>.

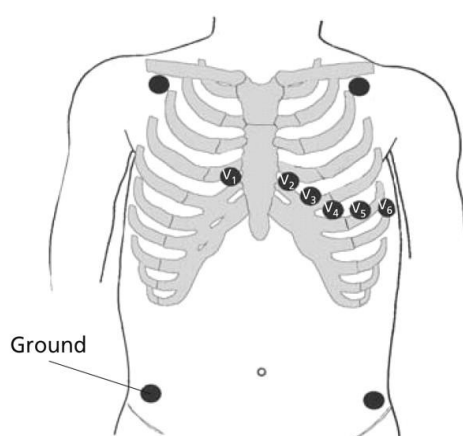


## Appendix 2: Electrocardiography in the paediatric population <sup>6</sup>

In infants and children the recording method is similar to that described for adults with some exceptions. To reduce artefact and improve the ECG quality, in infants and children ensure a patient and child friendly approach.

The ECG is performed with the patient in a supine position; however, if the patient is restless and distressed the procedure may be performed with the patient in a sitting position.

Standard precordial and limb lead placements apply however for restless infants and young children the Mason-Likar lead placement can be employed - 4 limb electrodes are placed anteriorly on the left and right shoulder and left and right side of the lower torso to prevent artefact caused by the movement of the arms and legs.



### Mason-Likar Lead placement <sup>9</sup>

On special request of a medical officer, additional precordial leads may be requested.

Electrode	Position
V3R and V4R	Mirror image of V3 and V4 on the right side of the chest.

When recording the ECG in paediatrics the paper speed and voltage is kept at the standard settings (25mm/s @ 10mm/mV). Any changes to the standard settings should be clearly marked on the printed ECG recording.

**Note:** When an electrocardiogram is presented for analysis (diagnosis), any variation from the usual recording procedure must be clearly and indelibly stated.

## Appendix 3: The recommended approach to recording the 12-lead ECG in the patient with dextrocardia <sup>6</sup>.

Dextrocardia is the term used to describe the condition where the heart is located within the right side of the chest cavity. Dextrocardia may be associated with situs inversus which is a condition where all of the patient's organs are in a mirror-image position.

***From the standard 12 lead resting ECG, dextrocardia and/or situs inversus may be suspected by the following:***

### **Dextrocardia-Situs Solitus**

#### **What to look for:**

- Q-waves in leads I and aVL
- Large R waves in leads V2 and V3
- R-wave regression in the precordial leads
- Normal looking limb leads

#### **Recording ECG:**

- Reverse precordial leads to right side
- Leave limb leads in their normal position

### **Situs Inversus**

#### **What to look for:**

- Inverted P-wave in lead I
- Lead I - the major QRS deflection is negative and T wave inverted
- Lead aVR resembles lead aVL and vice versa.
- R wave regression in precordial leads.

#### **Recording ECG:**

- Reverse precordial leads to right chest position
- Reverse the arm leads and leave leg leads in normal position

**Note:** Accidental reversal of the right and left arm connections may give an erroneous inverted P wave in lead I. Firstly eliminate technical errors in these instances prior to suspecting dextrocardia.

**If dextrocardia is suspected on initial ECG, a second ECG should be recorded. To perform the second ECG in these patients place the chest electrodes on the right side of the chest using the same intercostal spacing and anatomical landmarks as on the left side.**

Placement of the chest leads on the right side of the chest will provide a 'true' ECG representation. The limb lead complexes will continue to appear inverted, demonstrating

the abnormal location of the heart. However, the re-positioned chest leads will now show the appropriate R wave progression.

**When the electrodes have been repositioned and a recording has been acquired, it is important to clearly annotate the repositioned electrodes (For example, V3R, V4R etc).**

Both of the annotated ECGs should be retained.

**Note:** Swapping of the right and left limb leads will 'normalise' the appearance of the limb leads. If this approach is preferred it is imperative that the ECG is very clearly annotated to prevent the possibility of the dextrocardia being overlooked<sup>6</sup>.



Appendix 4: 15 lead for identifying inferior and right ventricular infarction.

- Indications for 15 lead ECG:
  - ECG changes (Q waves/ST segment shift) in leads II, III and aVF suggesting inferior wall ischemia or infarction
  - Evidence of inferior wall ischemia in leads II, III and aVF
  - Upon medical officer's request
- Right-sided leads V4R, V5R, and V6R are necessary to assess for a possible right ventricular infarct <sup>10</sup> in addition to the standard 12 lead recording (refer to manufactures instructions regarding connection of these addition leads to the ECG module)
- Attach the right sided leads to the patient in correct anatomical positions as follows:

V4R	Mid-clavicular line in the 5 <sup>th</sup> intercostal space on right chest wall
V5R	Anterior axillary line on 5 <sup>th</sup> intercostal space on right chest wall
V6R	Mid-axillary line on 5 <sup>th</sup> intercostal space on right chest wall

- Record the 15 lead ECG as per manufactures instructions
- Ensure to correctly label the leads on the recorded ECG as V4R, V5R, V6R with a black pen and not a pencil.

**Note:** If a significant arrhythmia is identified, refer to senior staff for clinical review.



## 9. References and Suggested Reading

### 9.1. References

1. Queensland Health. Informed decision making in health care 2012: Available from: <http://www.health.qld.gov.au/consent/default.asp>.
2. National Health and Medical Research Council. Australian Guidelines for the Prevention and Control of Infection in Healthcare. National Health and Medical Research Council; 2010 [cited 2012 12/09/12]; CD33:[Available from: <http://www.nhmrc.gov.au/node/30290>].
3. Kligfield P, Gettes LS, Bailey JJ, Childers R, Deal BJ, Hancock EW, et al. Recommendations for the standardization and interpretation of the electrocardiogram: part I: The electrocardiogram and its technology: a scientific statement from the American Heart Association Electrocardiography and Arrhythmias Committee, Council on Clinical Cardiology; the American College of Cardiology Foundation; and the Heart Rhythm Society: endorsed by the International Society for Computerized Electrocardiology. *Circulation*. [Practice Guideline Review]. 2007 Mar 13;115(10):1306-24.
4. Mason JW, Hancock EW, Gettes LS, American Heart Association E, Arrhythmias Committee CoCC, American College of Cardiology F, et al. Recommendations for the standardization and interpretation of the electrocardiogram: part II: Electrocardiography diagnostic statement list: a scientific statement from the American Heart Association Electrocardiography and Arrhythmias Committee, Council on Clinical Cardiology; the American College of Cardiology Foundation; and the Heart Rhythm Society: endorsed by the International Society for Computerized Electrocardiology. *Circulation*. [Practice Guideline Review]. 2007 Mar 13;115(10):1325-32.
5. Kadish AH, Buxton AE, Kennedy HL, Knight BP, Mason JW, Schuger CD, et al. ACC/AHA clinical competence statement on electrocardiography and ambulatory electrocardiography: A report of the ACC/AHA/ACP-ASIM task force on clinical competence (ACC/AHA committee to develop a clinical competence statement on electrocardiography and ambulatory electrocardiography). 2001.
6. The Society for Cardiological Science & Technology. Clinical Guidelines by Consensus: Recording a standard 12-lead electrocardiogram: An Approved Methodology 2010: Available from: [http://www.scst.org.uk/pages/page\\_box\\_contents.asp?pageid=808](http://www.scst.org.uk/pages/page_box_contents.asp?pageid=808).
7. Jowett NI, Turner AM, Cole A, Jones PA. Modified electrode placement must be recorded when performing 12-lead electrocardiograms. 2005.
8. Goldberger AL. *Clinical electrocardiography : a simplified approach*. St. Louis: Mosby; 1999.
9. Welinder A, Sornmo L, Feild DQ, Feldman CL, Pettersson J, Wagner GS, et al. Comparison of signal quality between EASI and Mason-Likar 12-lead electrocardiograms during physical activity. 2004.



10. Goldberger A. Electrocardiogram in the diagnosis of myocardial ischemia and infarction. UpToDate [serial on the Internet]. 2012: Available from: [http://www.uptodate.com/contents/electrocardiogram-in-the-diagnosis-of-myocardial-ischemia-and-infarction?source=search\\_result&search=electrocardiogram+in+the+diagnosis+of+myocardial&selectedTitle=1~150](http://www.uptodate.com/contents/electrocardiogram-in-the-diagnosis-of-myocardial-ischemia-and-infarction?source=search_result&search=electrocardiogram+in+the+diagnosis+of+myocardial&selectedTitle=1~150).
11. Huszar RJ. Basic dysrhythmias : interpretation & management. St. Louis: Mosby; 2002.
12. Hampton JR. The ECG made easy. Edinburgh; New York: Elsevier/Churchill Livingstone; 2008.

## 9.2. Suggested readings

For patient preparation:

- American Heart Association (AHA) Electrocardiography Guidelines Part 1 & 2 (2007) <sup>3, 4</sup>

ECG interpretation

- Basic Dysrhythmias Interpretation & Management 3rd Ed, Robert J Huszar <sup>11</sup>
- The ECG Made Easy 6th Ed, John R Hampton <sup>12</sup>

